



Número	Entrada	Salida
--------	---------	--------

ESPECIE:

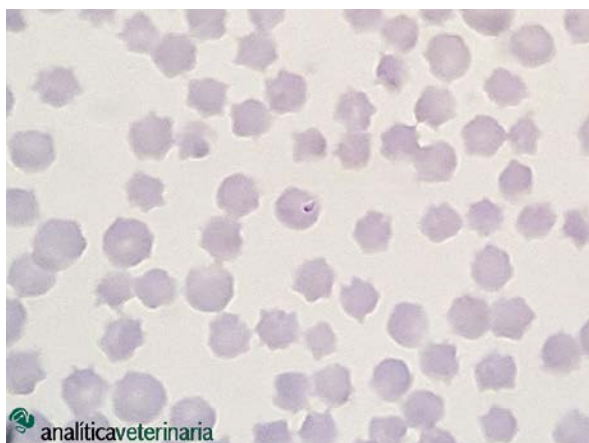
Bovino

MUESTRAS

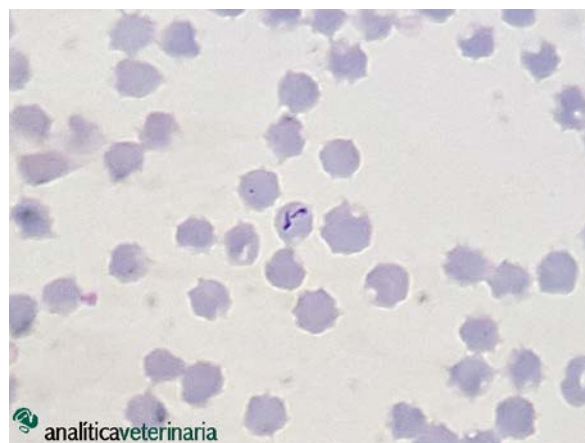
4 Sangre

IMAGENES MICROSCÓPICAS

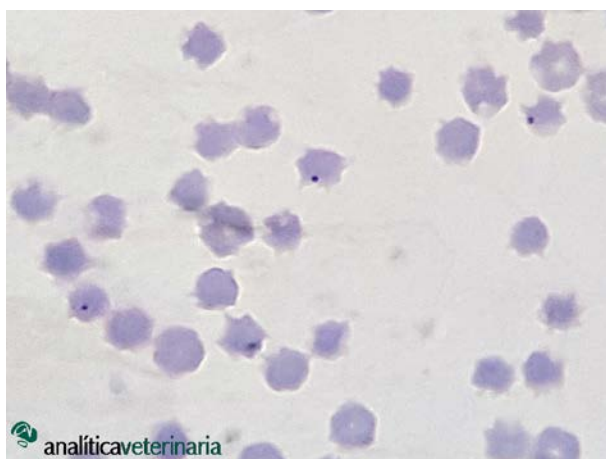
Babesiosis, theileriosis y anaplasmosis bovina. Muestras de sangre de cuatro vacas con síntomas de anemia. Se observan microscópicamente cuerpos patógenos intraeritrocitarios de morfología compatible con *Babesia* spp, *Theileria* spp y *Anaplasma* spp.



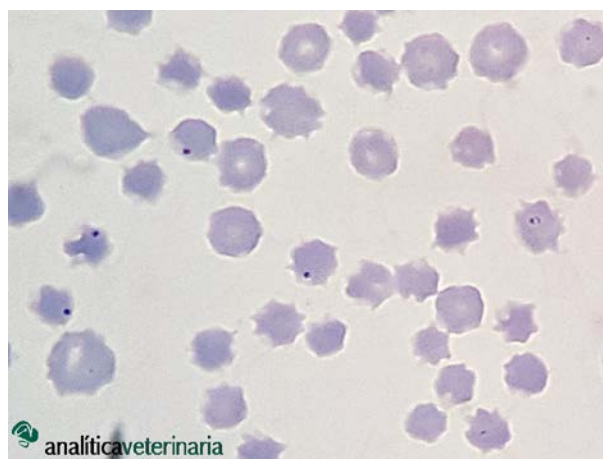
1. Sangre ref 25. *Theileria* spp



2. Sangre ref. 85. *Babesia* spp (prov. *B. bigemina*)

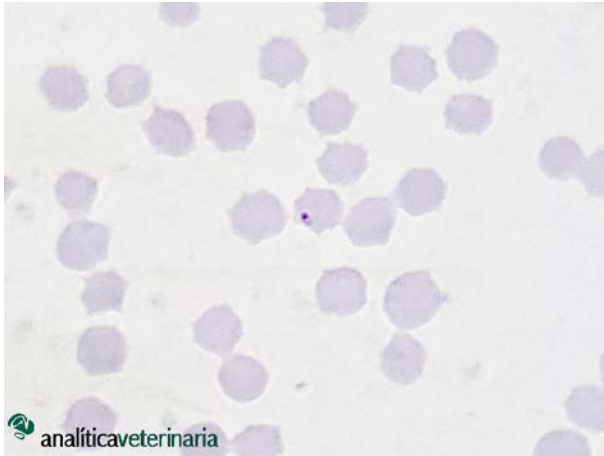


3. Sangre ref. 112. *Anaplasma* spp



4. Sangre ref. 112. *Anaplasma* spp y *Theileria* spp

INFORME REF.



5. Sangre ref. 7906. *Theileria* spp

ANALITICA VETERINARIA